

Deep endometriosis: definition, diagnosis, and treatment

Philippe R. Koninckx, Ph.D.,^{a,b,c,d} Anastasia Ussia, M.D.,^d Leila Adamyan, Ph.D.,^e Arnaud Wattiez, Ph.D.,^f and Jacques Donnez, Ph.D.^g

^a KU Leuven, Leuven, Belgium; ^b Oxford University, Oxford, United Kingdom; ^c Università del Sacro Cuore, Rome, Italy;

^d Gruppo Italo Belga, Leuven-Rome, Villa del Rosario, Rome, Italy; ^e Moscow State University, Moscow, Russia;

^f University of Strasbourg, Strasbourg, France; and ^g Université Catholique de Louvain, Brussels, Belgium

Deep endometriosis, defined as adenomyosis externa, mostly presents as a single nodule, larger than 1 cm in diameter, in the vesicouterine fold or close to the lower 20 cm of the bowel. When diagnosed, most nodules are no longer progressive. In >95% of cases, deep endometriosis is associated with very severe pain (in >95%) and is probably a cofactor in infertility. Its prevalence is estimated to be 1%–2%. Deep endometriosis is suspected clinically and can be confirmed by ultrasonography or magnetic resonance imaging. Contrast enema is useful to evaluate the degree of sigmoid occlusion. Surgery requires expertise to identify smaller nodules in the bowel wall, and difficulty increases with the size of the nodules. Excision is feasible in over 90% of cases often requiring suture of the bowel muscularis or full-thickness defects. Segmental bowel resections are rarely needed except for sigmoid nodules. Deep endometriosis often involves the ureter causing hydronephrosis in some 5% of cases. The latter is associated with 18% ureteral lesions. Deep endometriosis surgery is associated with late complications such as late bowel and ureteral perforations, and recto-vaginal and uretero-vaginal fistulas. Although rare, these complications require expertise in follow-up and laparoscopic management. Pain relief after surgery is excellent and some 50% of women will conceive spontaneously, despite often severe adhesions after surgery. Recurrence of deep endometriosis is rare. In conclusion, defined as adenomyosis externa, deep endometriosis is a rarely a progressive and recurrent disease. The treatment of choice is surgical excision, while bowel resection should be avoided, except for the sigmoid. (*Fertil Steril*® 2012;98:564–71. ©2012 by American Society for Reproductive Medicine.)

Discuss: You can discuss this article with its authors and with other ASRM members at <http://fertstertforum.com/koninckxpr-deep-endometriosis-diagnosis-treatment/>



Use your smartphone to scan this QR code and connect to the discussion forum for this article now.*

* Download a free QR code scanner by searching for "QR scanner" in your smartphone's app store or app marketplace.

The number of articles on endometriosis has increased exponentially over recent decades, creating problems (1) of quality. Furthermore, evidence-based medicine (EBM), which aims to apply the best available evidence gained from scientific methods, has the tendency to consider everything that is not proven as untrue, thus disregarding valuable observational information. This contributes to controversy, especially in surgery. Indeed, randomized controlled trials (RCTs) for rare and complex pathologies (e.g., hemorrhagic ascites or müllerianosis) are practically impossible to conduct because of the numbers required (2, 3). Surgical series always

evaluate both the technique and the skill of the surgeon, whereas blinding is difficult to implement. For deep endometriosis, surgical series often deal with the entire range of this highly variable pathology, which breaches the strict inclusion and exclusion criteria of most RCTs.

Moreover, we lack an animal model for this disease (4). Most published series are small and nonrandomized. They all reflect a referral bias and choices made concerning diagnosis and surgery by a specific group. This, together with the fact that deep endometriosis is clinically highly variable, prevents a meta-analysis, or even a systematic review, of simple but obvious

questions such as the importance of size, localization, and depth of infiltration. In addition, many problems are too rare for meaningful conclusions. Indeed, to collect a series of only 80 cases of hydronephrosis, 20 years and 2400 interventions were needed (5).

Therefore, in the light of available data we chose not to write a systematic review because this would only highlight controversy while everything considered "unproven" would be left out. Instead, an authority-based review is presented, reflecting the joint surgical experience of >8,000 cases of deep endometriotic nodules and numerous discussions during congresses and live surgery.

DEFINITION OF DEEP ENDOMETRIOSIS

Deep endometriosis was defined arbitrarily as endometriosis infiltrating the peritoneum by >5 mm (6). Microscopically, this definition included both

Received June 4, 2012; revised July 5, 2012; accepted July 6, 2012.

P.R.K. has nothing to disclose. A.U. has nothing to disclose. L.A. has nothing to disclose. A.W. has nothing to disclose. J.D. has nothing to disclose.

Reprint requests: Philippe R. Koninckx, Ph.D., vuilenbos 2, B 3360 Bierbeek, Belgium (E-mail: Pkoninckx@gmail.com).

Fertility and Sterility® Vol. 98, No. 3, September 2012 0015-0282/\$36.00

Copyright ©2012 American Society for Reproductive Medicine, Published by Elsevier Inc.

<http://dx.doi.org/10.1016/j.fertnstert.2012.07.1061>

adenomyosis externa and deeper typical lesions (described as type I). Typical lesions are multifocal and surgically less demanding. Nodules of adenomyosis externa (type II and type III lesions) are generally unique at the level of the rectum, rectosigmoid, sigmoid, or vesicouterine fold. Occasionally, two nodules are present, whereas three nodules are extremely rare (in the experience of the authors, <1 in 1,000). The difficulty of accurate depth estimation, has led to the inclusion of variable numbers of typical lesions in most published series, the percentages of which differs between groups. This has created confusion in the literature because the pathology of the lesions is rarely mentioned. In addition, that deep endometriosis surgery has become a skill label has contributed to the problem of including typical lesions.

We therefore suggest that deep endometriosis should be pathologically defined as adenomyosis externa—suggested as early as 1990 (7)—making it a homogeneous entity. In this article, this definition of adenomyosis externa will be used.

PREVALENCE, PAIN, AND INFERTILITY

The prevalence of deep endometriosis varies according to recognition and diagnosis, but it is estimated to be just a few percent of the population (8). Most women have severe pain, but an estimated 5% are pain free (no hard data available). After surgery, half will conceive spontaneously (9), suggesting a cause-and-effect relationship between deep endometriosis and infertility.

During the past two decades, the prevalence has apparently increased. Based on our experience in developing centers for deep endometriosis surgery in Oxford, Rome, and Strasbourg, we consider that this reflects growing awareness and referral. In addition, the inclusion of larger typical lesions contributes to this apparent increase.

PATHOPHYSIOLOGY AND NATURAL HISTORY: NOT PROGRESSIVE OR RECURRENT

The pathophysiology of endometriosis remains a subject of debate. It is still unclear whether endometrial and endometriotic cells are genetically different (10), or whether observed differences are the consequence of different environments (11, 12) or of preexisting immunologic defects (13). The fact that deep and cystic endometriosis are both clonal in origin, strongly (14–16) suggests some underlying genetic mutation. Associated differences in the endometrium appear to reflect a genetic predisposition.

Deep endometriosis should not be considered a progressive disease. Although an endometriotic lesion must clearly have been growing at some point, we challenge the concept of unavoidable progression after implantation because to our knowledge, a transition from typical to cystic or deep lesions was never observed. Deep endometriotic lesions that were not removed after diagnosis were not found to be progressive, some with a follow-up of 10 years. Although exact data are not available and mainly reflect nodules that are not painful, the joint experience of the authors suggests progression in only 1 nodule out of 20. This concept of no or low progression is moreover consistent with clinical observations

that most women experience severe pain for many years, often decades. In addition, the diameter of the nodules does not increase with age or duration of symptoms (unpublished observations). Indirect evidence in the Leuven area confirms this concept. Indeed, Ivo Brosens (personal communication) investigated patients for endometriosis in the early 1980s. These women, diagnosed at the time with typical and cystic endometriosis, were not the same as those in whom deep endometriosis was diagnosed in the 1990s by PK or JD working in the same area.

Deep endometriosis should not be considered a recurrent disease. Although surgery is highly variable and good prospective data are lacking, recurrence rates of confirmed deep endometriosis are convincingly low, that is, <5% (17, 18).

DIAGNOSIS AND DECISION TO PERFORM SURGERY FOR DEEP ENDOMETRIOSIS

By clinical examination, only 50% of deep endometriotic nodules >3 cm in diameter were diagnosed in the mid-1990s (19). With experience and awareness, the clinical diagnosis has probably improved. The most important conclusion, however, that the vast majority of deep endometriotic lesions will not be diagnosed by clinical examination, remains valid.

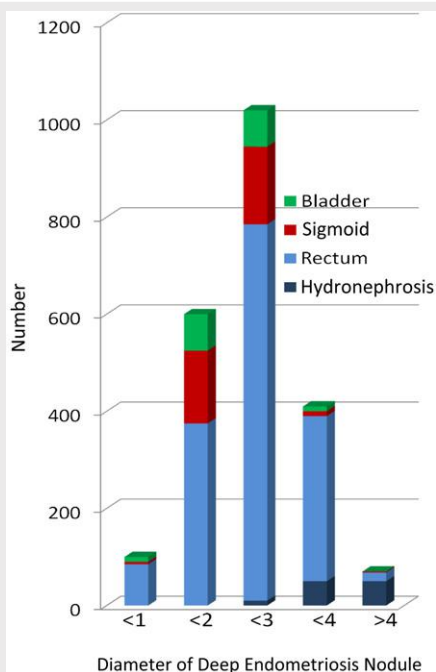
Deep endometriosis should be suspected in all women with invalidating hypogastric pain, especially dysmenorrhea, deep dyspareunia, severe chronic pain, mictalgia, and dyschezia. Most pathognomonic signs are severe dyschezia, menstrual blood on stools, menstrual diarrhea, severe menstrual mictalgia, and radiation of pain to the perineum (unpublished data). Although solid data linking these symptoms to size and localization of deep endometriosis are lacking, clinical symptoms remain key to suspecting deep endometriosis and deciding to perform surgery.

Clinical suspicion of rectal or rectosigmoid deep endometriosis can be confirmed by vaginal ultrasonography. The sensitivity and specificity of ultrasonography in the diagnosis of deep endometriosis remains unclear, and although reported to be >85% and even close to 100% (20), operators were never blinded to the clinical symptoms and rarely to the clinical examination. In addition, data linking sensitivity and specificity to the diameter and localization of the nodules are lacking. Most important, however, is that the accuracy of ultrasonography varies according to the expertise of the ultrasonographer. Answers to important questions such as sensitivity and specificity in the absence of clinical suspicion, or after a negative clinical exam, are missing. We suggest that ultrasonography is a useful tool when performed by an experienced ultrasonographer in dialogue with the clinician or surgeon. Conversely, ultrasonographic diagnosis of deep endometriosis in the absence of clinical symptoms should not be an indication for surgery. Although rare cases with silent hydronephrosis without clinical symptoms at routine ultrasonographic examination could contradict this statement, none of the authors have found this pathology, emphasizing that it must be extremely rare. Moreover, ultrasonographic examinations are not useful for the diagnosis of sigmoid endometriosis (20).

Clinical suspicion can be confirmed by magnetic resonance imaging (MRI). Magnetic resonance imaging might be less operator dependent and can also provide information about lesions at the level of the sigmoid, but the conclusions reached are similar to those of ultrasonographic examination (21–24). Typical images of a contrast enema can occasionally confirm a sigmoid or high rectosigmoid lesion. Colonoscopy is almost invariably negative. Only in rare cases of very large nodules (Fig. 1) with a high degree of bowel occlusion will colonoscopy be positive. The prevalence is estimated to be <5 in 1,000 cases. CA125 measurement is not very useful for the management of deep endometriosis, although sensitivity and specificity are >80% (25).

In conclusion, deep endometriosis is suspected or diagnosed clinically and the clinical suspicion can be confirmed by ultrasonography or MRI. Most important is close cooperation and dialogue between the surgeon and imaging specialist. The decision to perform surgery for deep endometriosis is mainly clinical. Ultrasonography and MRI can be useful tools to have a preoperative estimation of the size and lateral extension of lesions, larger lesions being more at risk of causing urinary retention after surgery (26). It remains debated (27), however, to what extent preoperative ultrasonography or MRI should influence the decision to perform surgery, or indeed the type of intervention to undertake for deep endometriosis.

FIGURE 1



Distribution of deep endometriosis by localization and by size. Lesions larger than 4 cm are rare, whereas hydronephrosis is found predominantly in lesions larger than 3 cm. Ureteral lesions were found exclusively in women with hydronephrosis and/or in women with nodules larger than 4 cm (from Leuven database spanning 1989–2011).

Koninckx. Deep endometriosis. *Fertil Steril* 2012.

PREOPERATIVE MANAGEMENT

Once the decision to perform surgery has been taken, a contrast enema is important, because it is the only examination that allows evaluation of the degree and length of bowel occlusion at the level of the sigmoid or high rectosigmoid. For the rectum, a contrast enema rarely provides additional information. Hydronephrosis should be excluded before surgery because it is associated with 18% of ureteral lesions during surgery and requires a preoperative ureteral stent (28).

A bowel preparation has traditionally been routinely given to all women scheduled for deep endometriosis surgery. Whether a bowel preparation is necessary for bowel resection has recently been challenged (29–32). It is unclear if these data can be extrapolated to conservative deep endometriosis excision, but evidence suggests that at least preoperative antibiotics should be given (30).

Transrectal MRI and transrectal ultrasonography have also been used to evaluate the depth of infiltration (33–35) and radial extension of deep endometriotic nodules. Infiltration up to the mucosa and invasion over >50% of the circumference were suggested as an indication for bowel resection (27, 35), but this remains a subject of debate (36).

In conclusion, before surgery, hydronephrosis should be identified because it requires preoperative ureteral stenting (28). Any partial bowel occlusion should also be diagnosed before surgery. As will be discussed, it remains unclear to what extent preoperative bowel examination should influence the decision regarding the type of surgery. We suggest that women with a bowel occlusion of >50% or longer than 2–3 cm should be scheduled for elective bowel resection. All other women should undergo excision of the nodule. If during surgery the nodule is found to be too big or invading the bowel wall too deeply, the skill and expertise of the surgeon should be weighted against the difficulty of discoid excision. In groups performing bowel resections liberally, preoperative management based on imaging was found to be highly variable (18), while ureteral stents were often inserted systematically.

SURGERY FOR DEEP ENDOMETRIOSIS

General Principles

Completeness of surgery with removal of all endometriosis sounds like a precept, as used in cancer surgery. However, evidence that endometriosis surgery needs to be 100% complete is lacking, although circumstantial evidence of the opposite exists. First of all, it is close to impossible to remove all endometrial/endometriotic cells from all sites. The discussion whether or not to remove all subtle or microscopic endometriosis is beyond the scope of this article. In >10% of cases of deep endometriosis, lymph nodes contain endometrial/endometriotic cells (37–39). To our knowledge, these lymph nodes never caused any clinical symptoms and fortunately systematic pelvic lymph node resection was not proposed. Second, deep endometriosis is surrounded by a fibrotic layer. It is unclear whether this layer should be removed or may be left behind. In the absence of evidence, it is remarkable that most of us have become less aggressive

surgically than 10 years ago, as discussed at a meeting in Atlanta between Camran Nezhat and the present authors. Third, recurrence rates of deep endometriosis requiring surgery are so low that it would be virtually impossible to demonstrate the need for complete versus near complete excision. Indeed, an increased recurrence rate from 1% to a few percent would be hard to prove. Finally, it remains unclear whether deep endometriotic nodules not causing pain should be excised when there is no evidence of progression. Moreover, many of these nodules probably go unnoticed, without doing any apparent harm.

Absence of evidence that all remaining endometriotic cells should be removed to reduce recurrence rates or improve pain or infertility outcome is very different from carrying out incomplete surgery by leaving a large part of the nodule behind. Clinical impressions confirmed by reviewing our database suggest that the most difficult surgeries of long duration were indeed those performed in women who had been operated on before, leaving deep endometriosis behind because of massive adhesions. Similar observations were made in women who had undergone several IVF cycles with oocyte pickup, and puncture through a deep endometriotic nodule. We therefore suspect that trauma to endometriotic nodules could reactivate the disease, causing growth and massive adhesions. Surgery of “fresh” nodules, never previously operated, is anticipated as being technically much easier.

In conclusion, in the absence of solid evidence, we suggest that deep endometriosis surgery should be visually complete, but at the level of the bowel, a rim of fibrosis can be left behind. Because we found most recurrences at the posterior fornix of the vagina, and because the vaginal cuff heals well, we specifically emphasize completeness at this level.

Discoid Excision

Excision of deep endometriosis can be technically demanding and the surgeon should balance his skills against the anticipated difficulty and duration of surgery. A technically difficult and long surgery should be expected when the nodule is >3 cm in diameter, when it is firmly attached to the ischial spine, when localized in the sigmoid, or when adhesions are expected because of previous incomplete surgery or IVF (unpublished data from the Leuven database, confirmed clinically by all authors). Especially when surgery exceeds 4–5 hours, the surgeon should be aware that fatigue can impair judgment (40). This highlights the need for a team with an assistant experienced in deep endometriosis surgery.

Instruments should be adequate. First, a high-flow insufflator allowing a flow >20 L/min is necessary to prevent loss of pneumoperitoneum when a bleeding requires continuous aspiration. Second, a uterine manipulator should be used to push the uterus into anteversion and to prevent loss of pneumoperitoneum when the vagina is opened. A CO₂ laser is not required but may facilitate and speed up surgery. There is no evidence today that robotic surgery is an advantage (41, 42).

Over the years, the technique has become streamlined and close to identical in all patients. Obviously not all steps are required in all patients, but the sequence rarely differs. The steps

we suggest for deep endometriosis excision from the rectum or rectosigmoid are as follows, and it is important to stick to these steps, especially when surgery is difficult.

Step 1. The plane of cleavage between the bowel and the side wall has to be identified, beginning from the pelvic brim. This will free the ovaries from the side wall permitting to fix them to the anterior wall. Together with lysis of physiologic adhesions of the sigmoid, this allows good visualization of the pelvis, without excessive Trendelenburg.

Step 2. Both ureters need to be identified if close to or involved in the endometriotic nodule being dissected. If hydronephrosis was missed before surgery, a ureteral stent should be placed. Endometriosis close to or even surrounding the ureter without hydronephrosis should not be considered a major problem and does not require a stent, because ureteral lesions occur in <0.5% of cases (28). When in doubt, however, it is preferable to insert a stent, a major risk being the surgeon who wants to prove he can do without one. When hydronephrosis is present, the stricture can be removed (over the stent) without a lesion in >80% of patients (28). If a lesion of the ureter is identified, or if part of the ureter is very thin, especially when >2 cm, repair has to be done either by prophylactic suturing or by resection and end-to-end anastomosis. Following this step, the lateral margins of the nodule should be completely dissected.

Step 3. The posterior/dorsal margin of the nodule is dissected. When strongly attached to the ischial spine and/or ischiosacral ligament, dissection should be very careful because of the risk of massive bleeding that can be difficult to control. At the end of this step, the pararectal spaces are identified and should be free of disease. Care is taken to complete this step before dissection of the nodule from the bowel is started. Indeed, possible lateral attachments of the nodule to the uterosacral ligaments or cervix and attachment medially to the bowel should be carefully dissected. The end result should see the endometriotic nodule remaining attached to the central part between the bowel and the uterus. Pushing the uterus into anteversion will elevate the nodule with the bowel hanging from it.

Step 4. Dissection of the nodule from the bowel is then performed. First, the anatomy should be identified. Larger nodules of the rectosigmoid are often associated with a bowel loop attaching the rectosigmoid to the uterus above the nodule. This increases the technical difficulty, because a rectal probe cannot reach this loop. Technically, during this dissection, the margin of the nodule is followed when dissecting from the bowel. When the muscularis of the bowel is reached, dissection with cold scissors is suggested with minimal coagulation in order to prevent late bowel lesions. This dissection will often include resection of part of the bowel muscularis up to the mucosa. During this dissection, small perforations of the mucosa may occur. Although 10 years ago such injury was considered inevitable and necessary to achieve complete excision, today we prefer to avoid this by leaving a fibrosis layer. Full-thickness resection with resection of a larger part of the mucosa is rare and necessary only for lesions infiltrating the bowel lumen, that is, those visible by rectoscopy. Aggressive coagulation of the bowel wall, especially when thin, is avoided. We suture and close any mucosal lesions

immediately in order to keep the duration of the bowel opening as short as possible.

Step 5. Dissection from the vagina is finally carried out as a last step. Care is taken not to enter the cervix, which has a similar consistency as a nodule. Dissection of the vagina is facilitated by use of a fornix presenter; often, small endometriotic cysts indicate that the vaginal mucosa is close and that part of the vaginal fornix should be removed.

Following careful hemostasis, the vaginal cuff, if opened, is closed. We close a muscularis defect of the rectum with a single-layer running transversal suture. A full-thickness defect is sutured in two layers. Finally, the pelvis and the upper abdomen are washed until the liquid runs clear. This may be a painstakingly long procedure, because often up to 8 L of solution is required.

Several technical variations of discoid excision exist. A circular stapler can be used to remove/suture part of the bowel wall, especially in case of smaller nodules, instead of risking a small bowel hole and double suture. It is unclear whether a running suture is superior to single sutures for muscularis or full-thickness defects. It is also unclear which size of bowel defect can be sutured and when a bowel resection becomes necessary. We consider that bowel resection should be contemplated whenever a defect of >50% of its circumference is present or when the muscularis defect is >7–8 cm long. Although technically feasible, this suturing is challenging for the surgeon, though too rare for anybody to have any meaningful experience.

For the sigmoid, the technique is essentially identical. It is advisable to start by fixing the bowel to the round ligaments in order to pull the sigmoid downwards and decrease mobility. Excision of sigmoid nodules is always difficult, because it frequently requires full-thickness resection as the nodule is often localized mesenterically, thus impairing blood flow after excision, because of the mobility of the sigmoid, and because suturing high in the pelvis is technically difficult. In addition, excision of a sigmoid nodule should be balanced against sigmoid resection, knowing that sigmoid resection can be done with minimal short- and long-term risks. This strongly suggests that difficult discoid resection of the sigmoid should preferably be replaced by bowel resection.

Bowel Resection

Steps 1 to 3 should be identical for discoid and bowel resection. The most important thing to realize is that if dissection is started between the nodule and vagina, bowel resection becomes almost inevitable. As described for the sigmoid, dissection between the nodule and vagina will end with a mobile rectum, with the nodule attached to it. Dissection of the nodule then becomes difficult. The technique and pitfalls of bowel resection with a circular stapler are beyond the scope of this article.

Bladder Endometriosis

Bladder endometriosis, even when requiring full-thickness resection, can be managed by laparoscopic surgery provided care is taken not to damage the intramural part of the ureter.

For this reason, a stent should be inserted when the lesion is close to the ureter, and the bladder should be opened as high as possible, permitting identification of the exact localization of the uretr. The bladder wall is sutured in two layers (although some consider one layer to be sufficient) and a bladder catheter is left in place for 7–10 days. It is unclear whether bladder healing should be checked afterwards.

Discussion of Surgery

When discoid excision or bowel resection should be done remains debatable. In two systematic reviews, we demonstrated that the leakage rate and long-term consequences of bowel resection increase when the resection involves the lower part of the bowel. For sigmoid resection, leaks occur in <1% of cases, almost without long-term problems. For low rectal resections, leaks increase to 15% or more and carry a lifelong risk of bowel, bladder, and sexual problems of 30%, 30%, and 40%, respectively (43). Of almost 2,000 bowel resections for endometriosis published to date, the large majority were lower resections. It remains unclear, however, what the exact indications were for bowel resection, because it is highly variable between authors. The size of nodules is rarely indicated, the length of resection ranges from 5 to 25 cm, and the duration of surgery can be as long as 8 hours, whereas data on sexuality after surgery are lacking (18). Besides the observation that most articles merely describe feasibility in small series, it is obvious that many groups almost exclusively perform bowel resections and for various reasons. Apart from the indications mentioned, we should be aware of many other aspects influencing surgery that are rarely mentioned in articles. Bowel resection is not only technically easier and faster than discoid excision, but it by definition makes the bowel surgeon coresponsible, which is medicolegally important, especially in countries where gynecologists should not perform bowel surgery. In addition, the fact that reimbursement of bowel resection is 5–10 times higher than discoid excision might be an argument for some hospitals.

We therefore suggest that discoid excision should at least be attempted for all rectosigmoid and rectal nodules. If too difficult for the level of expertise of the surgeon, bowel resection can be performed. In what percentage of cases a bowel resection should be performed is unclear. For the rectum and rectosigmoid, we (PK) performed <1% bowel resections. This very low rate of resections is partially an historical consequence of PK developing the technique together with the bowel surgeons he had trained in Leuven. When discussing which technique should be used, it remains important that deep endometriosis surgery is not a skill contest. What is important is that the incidence of bowel resection should progressively decrease with expertise from 15%–20% to much less. An incidence of >50% of bowel resections signals a surgical choice, not a technical necessity. For sigmoid lesions, we should be much more liberal with bowel resections. To identify the limits of conservative surgery, we (PK) today perform 5% elective bowel resections for deep sigmoid endometriotic nodules, and another 5% is decided during surgery. It can be argued that sigmoid endometriosis should be treated

conservatively only in case of small lesions and by experienced surgeons.

We strongly oppose bowel resection that is decided upon before surgery, except in case of the sigmoid showing signs of extensive occlusion. Indeed, some lesions erroneously can be judged as endometriosis or as invasive endometriosis. Although data are scarce, up to 14% of bowel resections were reported in which no endometriosis was subsequently found by pathology. Moreover, if we consider that in 12% of cases the endometriotic nodule was located outside the muscularis, this adds up to 26% of unnecessary bowel resections (44). This is confirmed by the fact that we have all seen lesions strongly suggestive of endometriosis, which during dissection proved to be no more than artifacts.

Considering the severe lifelong implications of bowel, bladder, and sexual problems following rectal and especially low rectal resection, we suggest that this procedure should not be performed when avoidable, which is the case in most women. This statement remains valid at least until it is demonstrated that complications for low rectal resection in case of endometriosis are different from those for other indications.

POSTOPERATIVE CARE

Antibiotics are given as one shot when the vagina has been opened, whereas full-thickness resection requires 7 days of antibiotic treatment. Following a muscularis defect and single-layer suture, or full-thickness resection and double-layer suture, the patient remains nil by mouth for 4 and 7 days, respectively.

Deep endometriosis surgery is associated with urinary retention and/or bladder dysfunction (45–47). The incidence is higher when nodules are bigger, extending laterally deep into the pararectal space. This is not surprising given the anatomy of the parasympathetic nerve. Nerve sparing is an illusion, because the parasympathetic nerve cannot be dissected from the endometriotic nodule: either endometriosis is left in place or part of the nerve is destroyed. Urinary retention generally resolves within a few weeks, occasionally after as long as 9 months. To prevent permanent bladder retention, we prefer to leave some endometriosis unilaterally, when complete excision of the nodule would risk damaging the parasympathetic nerve bilaterally.

Deep endometriosis may require ureteral and bowel surgery and is prone to complications. Postoperative care should therefore be meticulous and requires expertise. In the absence of strict and validated guidelines for the postoperative period, we use daily C-reactive protein levels, which should always go down progressively after day 3, and we advocate liberal use of repeat laparoscopy whenever in doubt.

The most severe complications during the first week are late bowel perforations and late ureteral perforations. A late bowel perforation is a potentially life-threatening event, recognized as early as 1996 (48). In >90% of cases, it occurs during the first few days after surgery, but can occasionally occur up to postoperative day 7. It requires immediate recognition and therapy, which demands expertise, because apart from a short episode of acute pain, clinical symptoms are minimal, the clinical examination is negative and C-reactive

protein levels are not yet increased. Although a contrast enema or computed tomographic scan can be helpful, an early repeat laparoscopy is recommended whenever in doubt. If performed within 24 hours after perforation, treatment can be conservative with a bowel suture and lavage, as demonstrated in >50 cases (PK, unpublished data). If a perforation is missed and diagnosis made after 24 hours, four-quadrant peritonitis will be found, necessitating a colostomy. Conservative treatment and repeated lavage have been performed occasionally, but this should be considered as experimental surgery. Late ureteral leakage should be treated with a stent inserted under laparoscopic vision and a stitch; following blind stent insertion, ureteral leaks will continue in 50% of cases (28).

Other complications are rectovaginal, ureterovaginal, and vesicovaginal fistulae. Although experience is limited, vesicovaginal and ureterovaginal fistulae can and should be treated immediately by laparoscopy, thus avoiding development of extensive fibrosis. Treatment of rectovaginal fistulae is less clear. We are in doubt whether to perform early repeat laparoscopy to close the defect, similar to our experience with vesicovaginal fistulae. Traditionally, however, it is advocated to wait at least 6 weeks because some of the smaller fistulae close spontaneously. Thereafter, bowel resection is generally performed, or occasionally conservative vaginal closure. Laparoscopic dissection with closure of the rectovaginal fistulae can be done after 6 weeks (only performed twice), but dissection is long and difficult.

In conclusion, postoperative care after surgery for deep endometriosis requires strict follow-up with early repeat laparoscopy to immediately treat any complications, including bleeding, infection, late ureteral or bowel perforation, or fistulae. When a complication occurs >2 weeks after surgery, the risks and advantages of immediate intervention should be balanced against the rule that between day 15 and 45, repeat interventions should be avoided if possible.

RESULTS

The results of rectovaginal surgery have been described in a number of excellent articles and reviews. Pain relief is unequivocally excellent, with >85% of women pain free (34). Recurrence rates, defined as recurrence of endometriosis, are low. The spontaneous fertility rate is 50%–60%. However, available data do not allow us to balance outcome against the size or localization of nodules, type of surgery performed, preoperative imaging, or pathology.

Postoperative adhesions after deep endometriosis surgery are poorly documented. In a recent RCT (in preparation), adhesions were surprisingly much more severe than anticipated in most women.

DISCUSSION

Deep endometriosis should be considered a specific entity of endometriosis, to be defined as adenomyosis externa by pathology. This definition will avoid inclusion of slightly larger typical lesions in reports on deep endometriosis, which confound the data. Furthermore, it should not be considered a progressive and recurrent disease, until proven otherwise. This is extremely important when counseling patients.

Recurrence is suggested to be almost invariably a consequence of incomplete surgery.

Indications for deep endometriosis surgery are pain and/or infertility, and it is unclear whether a nodule without bowel occlusion that does not cause pain should be operated. Today, the indications should never be occasional findings by imaging techniques, in the absence of clinical symptoms.

The need for a bowel preparation is a matter of debate (29–32) for bowel resection. However, given the risk of late bowel perforation, we prefer to administer a full bowel preparation for discoid excision, until proven otherwise.

Preoperative management and the predictive value of imaging remain a source of controversy. Although transvaginal ultrasonography and MRI are useful to confirm the clinical diagnosis or suspicion, these examinations unfortunately cannot sufficiently predict the difficulty of surgery or the type of intervention required. It would indeed be useful to have examinations that could predict the difficulty of surgery, especially for inexperienced surgeons. Until then, we maintain the rule initiated in Oxford: do a laparoscopy and judge the difficulty. If too difficult, refer without further surgery. Other procedures such as transrectal ultrasonography or MRI cannot predict the need for bowel resection either. Data are lacking to demonstrate even a predictive value. We believe that only a contrast enema can predict the degree of sigmoid obstruction, and this examination is therefore useful to decide about elective sigmoid resection.

The completeness of resection of deep endometriosis remains under discussion. We suggest that for the bowel, a small layer of fibrosis can be left behind, thus further reducing the need for bowel resection. Bowel resections are often avoidable, although in 8% of cases, margins are not free. Considering the number of unnecessary and avoidable bowel resections, we strongly suggest always trying discoid excision and deciding only during surgery what type of intervention should be made. The decision to perform a bowel resection should not be taken before surgery, except in case of an occlusive nodule in the sigmoid. Because shaving suggests layer-by-layer excision, which contrast with the idea of en bloc excision of deep endometriosis as described, we prefer to use the terms *discoid excision* or *en bloc excision*.

Deep endometriosis surgery is challenging and complication prone. As a first line of prevention, we recommend avoiding interventions that take more than 5 hours because of fatigue of the surgeon. This implies that in the rare event of two nodules being present, for example, at the level of the rectum and the sigmoid, interventions should be performed in two steps, the alternative being a bowel resection of 25 cm. To demonstrate medicolegally that surgery was performed carefully, some of us advocate video recording of entire procedures (49). Without video recording, which can demonstrate unequivocally the need for intervention and type of surgery, reimbursement will remain at a much lower level than for bowel resection. Those interested in the evolution of ideas and techniques over time are invited to read a similar article written in 1996 (50).

Acknowledgments: For reviewing the manuscript and for their comments, we thank our current and former collaborators,

that is, Jean Squifflet, UCL, Belgium; Carlo De Cicco, Campus Biomedico Rome, Italy; Roberta Corona, Vrije Universiteit Brussel, Brussels, Belgium; Karina Mailova, Moscow State University, Moscow, Russia; Ron Shonman, Tel Aviv, Israel; John Koninckx, Leuven, Belgium; Mario Malzoni, Avelino, Italy; Alfonso Rosetti, Rome, Italy; Enda McVeigh, Oxford, United Kingdom; and Errico Zpi, Rome, Italy. We also thank authorities mentioned in the manuscript, such as Ivo Brosens, Leuven, Belgium, and Camran Nezhat, Atlanta, GA, for their help with its review.

REFERENCES

1. Koninckx PR, Batt RE, Hummelshoj L, McVeigh E, Ussia A, Yeh J. The elephant in the room: quality control of endometriosis data. *J Minim Invasive Gynecol* 2010;17:637–40.
2. Ussia A, Betsas G, Corona R, De CC, Koninckx PR. Pathophysiology of cyclic hemorrhagic ascites and endometriosis. *J Minim Invasive Gynecol* 2008;15:677–81.
3. Batt RE, Smith RA, Buck Louis GM, Martin DC, Chapron C, Koninckx PR, et al. Mullerianosis. *Histol Histopathol* 2007;22:1161–6.
4. Dehoux JP, Defrere S, Squifflet J, Donnez O, Polet R, Mestdagt M, et al. Is the baboon model appropriate for endometriosis studies? *Fertil Steril* 2011;96:728–33.
5. De CC, Ussia A, Koninckx PR. Laparoscopic ureteral repair in gynaecological surgery. *Curr Opin Obstet Gynecol* 2011;23:296–300.
6. Koninckx PR, Martin DC. Deep endometriosis: a consequence of infiltration or retraction or possibly adenomyosis externa? *Fertil Steril* 1992;58:924–8.
7. Cornillie FJ, Oosterlynck D, Lauweryns JM, Koninckx PR. Deeply infiltrating pelvic endometriosis: histology and clinical significance. *Fertil Steril* 1990;53:978–83.
8. Koninckx PR. Biases in the endometriosis literature. Illustrated by 20 years of endometriosis research in Leuven. *Eur J Obstet Gynecol Reprod Biol* 1998;81:259–71.
9. Donnez J, Squifflet J. Complications, pregnancy and recurrence in a prospective series of 500 patients operated on by the shaving technique for deep rectovaginal endometriotic nodules. *Hum Reprod* 2010;25:1949–58.
10. Koninckx PR, Barlow D, Kennedy S. Implantation versus infiltration: the Sampson versus the endometriotic disease theory. *Gynecol Obstet Invest* 1999;47(Suppl 1):3–9.
11. Koninckx PR, Kennedy SH, Barlow DH. Endometriotic disease: the role of peritoneal fluid. *Hum Reprod Update* 1998;4:741–51.
12. Koninckx PR. Biases in the endometriosis literature—illustrated by 20 years of endometriosis research in Leuven. *Eur J Obstet Gynecol Reprod Biol* 1998;81:259–71.
13. Oosterlynck DJ, Meuleman C, Waer M, Koninckx PR. CO₂-laser excision of endometriosis does not improve the decreased natural killer activity. *Acta Obstet Gynecol Scand* 1994;73:333–7.
14. Nabeshima H, Murakami T, Yoshinaga K, Sato K, Terada Y, Okamura K. Analysis of the clonality of ectopic glands in peritoneal endometriosis using laser microdissection. *Fertil Steril* 2003;80:1144–50.
15. Wu Y, Basir Z, Kajdacsy-Balla A, Strawn E, Macias V, Montgomery K, et al. Resolution of clonal origins for endometriotic lesions using laser capture microdissection and the human androgen receptor (HUMARA) assay. *Fertil Steril* 2003;79(Suppl 1):710–7.
16. Jimbo H, Hitomi Y, Yoshikawa H, Yano T, Momoeda M, Sakamoto A, et al. Evidence for monoclonal expansion of epithelial cells in ovarian endometrial cysts. *Am J Pathol* 1997;150:1173–8.
17. Roman H, Vassilief M, Gourcerol G, Savoye G, Leroi AM, Marpeau L, et al. Surgical management of deep infiltrating endometriosis of the rectum: pleading for a symptom-guided approach. *Hum Reprod* 2011;26:274–81.
18. De Cicco C, Corona R, Schonman R, Mailova K, Ussia A, Koninckx P. Bowel resection for deep endometriosis: a systematic review. *Br J Obstet Gynaecol* 2011;118:285–91.

19. Koninckx PR, Meuleman C, Oosterlynck D, Cornillie FJ. Diagnosis of deep endometriosis by clinical examination during menstruation and plasma CA-125 concentration. *Fertil Steril* 1996;65:280–7.
20. Hudelist G, English J, Thomas AE, Tinelli A, Singer CF, Keckstein J. Diagnostic accuracy of transvaginal ultrasound for non-invasive diagnosis of bowel endometriosis: systematic review and meta-analysis. *Ultrasound Obstet Gynecol* 2011;37:257–63.
21. Saba L, Guerriero S, Sulcis R, Pilloni M, Ajossa S, Melis G, et al. MRI and "tenderness guided" transvaginal ultrasonography in the diagnosis of recto-sigmoid endometriosis. *J Magn Reson Imaging* 2012;35:352–60.
22. Bazot M, Gasner A, Lafont C, Ballester M, Darai E. Deep pelvic endometriosis: limited additional diagnostic value of postcontrast in comparison with conventional MR images. *Eur J Radiol* 2011;80:e331–9.
23. Bazot M, Darai E. Value of transvaginal sonography in assessing severe pelvic endometriosis. *Ultrasound Obstet Gynecol* 2010;36:134–5.
24. Bazot M, Lafont C, Rouzier R, Roseau G, Thomassin-Naggara I, Darai E. Diagnostic accuracy of physical examination, transvaginal sonography, rectal endoscopic sonography, and magnetic resonance imaging to diagnose deep infiltrating endometriosis. *Fertil Steril* 2009;92:1825–33.
25. Muyldermans M, Cornillie FJ, Koninckx PR. CA125 and endometriosis. *Hum Reprod Update* 1995;1:173–87.
26. Ballester M, Santulli P, Bazot M, Coutant C, Rouzier R, Darai E. Preoperative evaluation of posterior deep-infiltrating endometriosis demonstrates a relationship with urinary dysfunction and parametrial involvement. *J Minim Invasive Gynecol* 2011;18:36–42.
27. Abrao MS, Podgaec S, Dias JA Jr, Averbach M, Silva LF, Marino de CF. Endometriosis lesions that compromise the rectum deeper than the inner muscularis layer have more than 40% of the circumference of the rectum affected by the disease. *J Minim Invasive Gynecol* 2008;15:280–5.
28. De Cicco C, Schonman R, Craessaerts M, Van CB, Ussia A, Koninckx PR. Laparoscopic management of ureteral lesions in gynecology. *Fertil Steril* 2009;92:1424–7.
29. Cao F, Li J, Li F. Mechanical bowel preparation for elective colorectal surgery: updated systematic review and meta-analysis. *Int J Colorectal Dis* 2012;27:803–10.
30. Cohen SL, Einarsson JJ. The role of mechanical bowel preparation in gynecologic laparoscopy. *Rev Obstet Gynecol* 2011;4:28–31.
31. Fanning J, Valea FA. Perioperative bowel management for gynecologic surgery. *Am J Obstet Gynecol* 2011;205:309–14.
32. Galandiuk S, Fry DE, Polk HC Jr. Is there a role for bowel preparation and oral or parenteral antibiotics in infection control in contemporary colon surgery? *Adv Surg* 2011;45:131–40.
33. Hudelist G, Tuttles F, Rauter G, Pucher S, Keckstein J. Can transvaginal sonography predict infiltration depth in patients with deep infiltrating endometriosis of the rectum? *Hum Reprod* 2009;24:1012–7.
34. Bassi MA, Podgaec S, Dias JA Jr, D'Amico FN, Petta CA, Abrao MS. Quality of life after segmental resection of the rectosigmoid by laparoscopy in patients with deep infiltrating endometriosis with bowel involvement. *J Minim Invasive Gynecol* 2011;18:730–3.
35. Goncalves MO, Podgaec S, Dias JA Jr, Gonzalez M, Abrao MS. Transvaginal ultrasonography with bowel preparation is able to predict the number of lesions and rectosigmoid layers affected in cases of deep endometriosis, defining surgical strategy. *Hum Reprod* 2010;25:665–71.
36. Koninckx PR, De CC, Schonman R, Corona R, Betsas G, Ussia A. The recent article "Endometriosis lesions that compromise the rectum deeper than the inner muscularis layer have more than 40% of the circumference of the rectum affected by the disease." *J Minim Invasive Gynecol* 2008;15:774–5.
37. Gong Y, Tempfer CB. Regional lymphatic spread in women with pelvic endometriosis. *Med Hypotheses* 2011;76:560–3.
38. Namkung J, Kim SJ, Kim JH, Kim J, Hur SY. Rectal endometriosis with invasion into lymph nodes. *J Obstet Gynaecol Res* 2011;37:1117–21.
39. Tempfer CB, Wenzl R, Horvat R, Grimm C, Polterauer S, Buerkle B, et al. Lymphatic spread of endometriosis to pelvic sentinel lymph nodes: a prospective clinical study. *Fertil Steril* 2011;96:692–6.
40. Schonman R, De CC, Corona R, Soriano D, Koninckx PR. Accident analysis: factors contributing to a ureteric injury during deep endometriosis surgery. *Br J Obstet Gynaecol* 2008;115:1611–5.
41. Nezhat C, Hajhosseini B, King LP. Robotic-assisted laparoscopic treatment of bowel, bladder, and ureteral endometriosis. *J Soc Laparoendosc Surg* 2011;15:387–92.
42. Nezhat C, Lewis M, Kotikela S, Veeraswamy A, Saadat L, Hajhosseini B, et al. Robotic versus standard laparoscopy for the treatment of endometriosis. *Fertil Steril* 2010;94:2758–60.
43. Ret Davalos ML, De Cicco C, D'Hoore A, De DB, Koninckx PR. Outcome after rectum or sigmoid resection: a review for gynecologists. *J Minim Invasive Gynecol* 2007;14:33–8.
44. Meuleman C, D'Hoore A, Van CB, Beks N, D'Hooghe T. Outcome after multidisciplinary CO₂ laser laparoscopic excision of deep infiltrating colorectal endometriosis. *Reprod Biomed Online* 2009;18:282–9.
45. Ballester M, Chereau E, Dubernard G, Coutant C, Bazot M, Darai E. Urinary dysfunction after colorectal resection for endometriosis: results of a prospective randomized trial comparing laparoscopy to open surgery. *Am J Obstet Gynecol* 2011;204:303.e1–6.
46. Gabriel B, Nassif J, Trompoukis P, Lima AM, Barata S, Lang-Averous G, et al. Prevalence and outcome of urinary retention after laparoscopic surgery for severe endometriosis—does histology provide answers? *Int Urogynecol J* 2012;23:111–6.
47. Kovoov E, Nassif J, Miranda-Mendoza I, Lang-Averous G, Wattiez A. Long-term urinary retention after laparoscopic surgery for deep endometriosis. *Fertil Steril* 2011;95:803–12.
48. Koninckx PR, Timmermans B, Meuleman C, Penninckx F. Complications of CO₂-laser endoscopic excision of deep endometriosis. *Hum Reprod* 1996;11:2263–8.
49. Koninckx PR. Videoregistration of surgery should be used as a quality control. *J Minim Invasive Gynecol* 2008;15:248–53.
50. Koninckx PR, Martin DC. Surgical treatment of deeply infiltrating endometriosis. In: Sutton C, editor. *Gynecological endoscopic surgery*. London: Chapman and Hall; 1997:19–35.