

Effect of Anterior Compartment Endometriosis Excision on Infertility

Gabriele Centini, MD, PhD, Karolina Afors, MD, Joao Alves, MD, István Máté Argay, MD, Philippe R. Koninckx, MD, PhD, Lucia Lazzeri, MD, PhD, Giorgia Monti, MD, Errico Zupi, MD, Arnaud Wattiez, MD, PhD

ABSTRACT

Background and Objectives: Laparoscopic surgical excision of bladder nodules has been demonstrated to be effective in relieving associated painful symptoms; the data are lacking concerning the impact of anterior compartment endometriosis on infertility. We conducted this study to evaluate whether or not the surgical excision of deep endometriosis affecting the anterior compartment plays a role in restoring fertility.

Methods: This multicentre, retrospective study included a group of 55 patients presenting with otherwise-unexplained infertility who had undergone laparoscopic excision of anterior compartment endometriosis with histological confirmation. Patient medical records and operative reports were reviewed. Telephone interviews were conducted for long-term followup of fertility outcomes.

Results: The pregnancy rate following surgical excision of endometriotic lesions was 44% (n = 11) among those with anterior compartment involvement alone and 50% (n = 15) in case of posterior lesions association without

any significant difference. The symptoms related to bladder endometriosis resolved in the 84.2% of the cases with a recurrence rate of 1.8% at the 2-year followup not requiring further surgery.

Conclusion: Laparoscopic excision of anterior compartment endometriosis is effective in restoring fertility in patients with otherwise-unexplained infertility and in treating endometriosis-related symptoms.

Key Words: Bladder endometriosis, Deep endometriosis, Infertility, Laparoscopy, Pregnancy rate.

INTRODUCTION

Urinary-tract endometriosis globally affects 0.3% to 6% of women with endometriosis, of which bladder involvement represents the most frequently encountered type of urinary-tract endometriosis, occurring in 84% to 90% of cases.¹⁻⁵

Urinary-tract endometriosis can be associated with several urinary symptoms due to its pattern of multifocal disease involvement such as painful bladder syndrome, voiding dysfunction and hematuria.⁶ It is not only isolated to bladder, but can also involve the ureters, urethra and kidney affecting both anterior and posterior pelvic compartments.

The contents of the anterior compartment of the pelvis include the bladder and urethra. These structures are located in the lesser pelvis, anterior to the uterus and vagina and posterior to the pubic symphysis. Deep infiltrating endometriosis of the anterior compartment consists of implants involving the bladder with varying degrees of penetration into the detrusor muscle, and involvement of surrounding structures such as the uterovesical fold and distal part of the ureter. Posterior compartment disease may include lesions of the retrocervical area, rectovaginal septum, rectum, uterosacral ligaments and posterior vaginal fornix. Involvement of the pelvic ureter is also often associated with posterior compartment nodules.

As with any type of endometriosis, urinary-tract endometriosis, treatment options depend on several factors such

Whittington Hospital (Dr. Afors), London, United Kingdom; Serviço de Ginecologia, Hospital da Luz (Dr. Argay), Lisboa, Portugal; Department of Obstetrics and Gynecology, University of Debrecen Clinical Center (Dr. Argay), Debrecen, Hungary; Department of Molecular and Developmental Medicine, University of Siena (Drs Centini, Lazzeri, and Monti), Siena, Italy; Department of Obstetrics and Gynecology, KU Leuven (Dr. Koninckx), Leuven, Belgium; University of Oxford (Dr. Koninckx), Oxford, United Kingdom; University Cattolica del Sacro Cuore (Dr. Koninckx), Roma, Italy; Moscow State University (Dr. Koninckx), Moscow, Russia; Gruppo Italo Belga (Dr. Koninckx), Villa del Rosario, Rome, Italy; Obstetrics and Gynecology Clinic, Department of Biomedicine and Prevention, University of Rome "Tor Vergata", Rome, Italy (Dr. Zupi); Department of Gynecology, University of Strasbourg, Strasbourg, France and Latifa Hospital, Dubai, United Arab Emirates (Dr. Wattiez).

Institutional Review Board approval: Siena ethics committee 12849 (February 19, 2018).

Disclosure statement: none.

Conflicts of Interest: All authors declare no conflict of interest regarding the publication of this article.

Informed consent: Dr. Centini declares that written informed consent was obtained from the patient/s for publication of this study/report and any accompanying images.

Address correspondence to: Dr. Gabriele Centini, MD, PhD, Università degli Studi di Siena, Sovicille, Siena, Italy. E-mail: centini.gabriele@gmail.com

DOI: 10.4293/JSLS.2018.00067

© 2018 by JSLS, Journal of the Society of Laparoendoscopic Surgeons. Published by the Society of Laparoendoscopic Surgeons, Inc.

as patient age, severity of symptoms, desire for pregnancy, ureteral proximity, or coexisting presence of endometriosis nodules at additional sites.⁷

Bladder nodules can be treated either via laparoscopy or cystoscopy. Cystoscopy is a useful technique to have a histology confirmation of the disease in case diagnostic doubt arise, to guide the cystectomy in case of large nodule to be economical on the detrusor muscle and to evaluate the ureteral ostia. However, in most cases the disease is extrinsic coming from the vesico-uterine fold, therefore a laparoscopic resection is often more complete and lead to less relapse.⁸

Although, laparoscopic surgical excision of bladder nodules has been demonstrated to be effective in relieving associated painful symptoms, there is a lack of data concerning the impact of anterior compartment endometriosis on infertility.^{9–12} In fact, the association of anterior disease and infertility has never been directly investigated, but data came out mainly from studies conducted for pain assessment.

The aim of this study is to evaluate the reproductive outcomes of patients with otherwise-unexplained infertility undergoing surgery for deep infiltrating endometriosis (DIE) involving the anterior compartment.

MATERIALS AND METHODS

We conducted a retrospective multicentre study including all patients of childbearing age (age < 40 years) who underwent laparoscopic treatment of DIE of the anterior compartment, with histological confirmation, in three tertiary referral university hospitals (“Strasbourg” University Hospital, Department of Gynecology; “Tor Vergata” University Hospital, Department of Biomedicine and Prevention; “Santa Maria alle Scotte” University Hospital, Department of Molecular and Developmental Medicine) between January 2010 and September 2014.

Among this group of patients, we selected those with otherwise-unexplained primary infertility lasting more than 1 year as main indication for surgery that attempted to conceive immediately after the procedure, with or without associated pain.

Institutional review board approval was obtained (protocol number 12489).

The concomitant involvement of the posterior compartment was not considered an exclusion criterion with the purpose to understand whether the presence of multiple lesions could cause a worsening of the fertility outcome.

All patients with abnormal uterine cavity, major menses abnormalities (any disturbance of regularity, frequency, heaviness and duration of flow),¹³ previous surgery for infertility or endometriosis, bilateral tubal occlusion or history of pelvic inflammatory disease, polycystic ovarian syndrome, and partner sperm count < 15 million/mL or sperm motility and morphology abnormalities were excluded.

Furthermore, the concomitant treatment of endometrioma at the time of surgery was considered an exclusion criterion.

All the selected patients were contacted to acquire the informed consent to participate in the study.

Data regarding location of endometriosis, operative treatment, intra-operative and postoperative complications were obtained from medical records. Preoperative findings, including symptom profile and additional investigations (magnetic resonance imaging, transvaginal ultrasound evaluations, tubal patency, and diagnostic hysteroscopy), were also collected.

All women were followed up by outpatient consultation after 1 month and by telephone interview between 12 and 24 months after surgery. Information regarding pain symptoms, fertility, type of conception (spontaneous/Assisted reproductive technologies (ART), and modality of delivery were also recorded.

None of the patients received any postoperative medical therapy given that the main goal for each patient was the search for pregnancy.

Successful conception was defined when embryonic cardiac activity is visualized by a transvaginal ultrasound.

All surgical procedures were performed by a single surgeon in each tertiary referral center (AW; EZ; GC) experienced in minimally invasive treatment of endometriosis. A careful evaluation of the entire abdominal cavity was performed in all cases, all visible endometriotic implants were removed and adhesions divided.

Surgical Technique

Concerning the laparoscopic treatment of the anterior compartment, the nodule resection was tailored to the depth of the detrusor muscle invasion in order to obtain a complete removal, but to spare, at the same time, as much bladder as possible.

The surgical technique used has been described previously and consists of anatomy restoration to delineate

the real dimension of the nodule.^{14,15} The first step is the opening of both paravesical spaces in their medial component between the bladder and the umbilical artery, to identify the limits of the bladder itself and the vesico-uterine plane, which is approached for the lateral part. The central and more sticky part of the lesion is therefore left as last to correctly identify the cleavage plane (**Figure 1**).

The nodule is left attached to the detrusor muscle and then shaved with monopolar hook trying to spare as much healthy tissue as possible. A partial cystectomy has been performed just in those cases where the DIE nodule was involving the bladder up to the mucosa otherwise a shaving technique was used (**Figure 2**).

In case of partial cystectomy, the bladder was sutured with a single layer 2-0 absorbable multifilament separate stitches, whereas in case of a not full thickness lesion a reinforcement of the muscle was performed with a continuous 2-0 monofilament. At the end of the procedure a continence test was systematically performed with 200 mL of physiologic solution and methylene blue, in case of leakage the suture was reinforced to be watertight (**Figure 3**).

The bladder healing and continence was assessed through a low-pressure cystography at least 10 days after the procedure.

Concerning the posterior compartment, the first step was to mobilize the sigma freeing it from physiological attachment in order to expose the left adnexa and develop the pararectal space to approach the disease from an area not distorted by the disease. In any case the path of the ureter

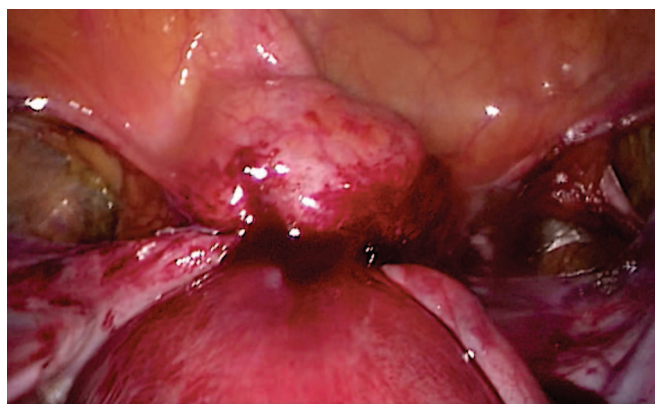


Figure 1. The Figure shows the appearance of a nodule of deep endometriosis affecting the bladder with the typical retraction of the surrounding structures including the round ligaments after the opening of both paravesical spaces.

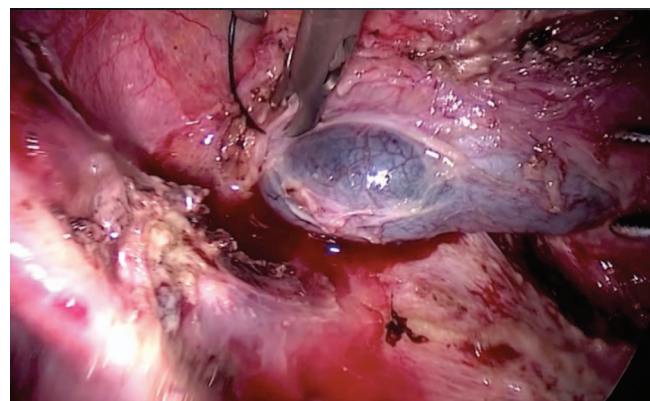


Figure 2. The Figure shows the shaving of a bladder nodule with skinning technique trying to spare the mucosa layer. To highlight the mucosa, methylene blue is instilled inside the bladder.

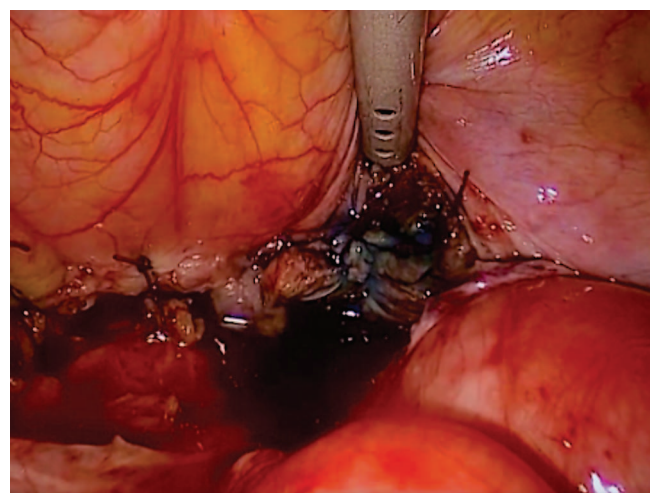

Figure 3. The picture shows security test after the closure of the bladder with separate stitches with a leakage at the right corner. The defect was closed with an extra stitch and then the test repeated.

was identified and mono or bilateral ureterolysis performed when needed. After the dissection, the bowel lesions were carefully evaluated and either a shaving, discoid, or segmental resection was performed depending on the extent and infiltration. Aiming to eradicate the disease a posterior colpectomy or ureteric resection and reanastomosis were performed when appropriate.¹⁶

Statistical Analysis

The statistical analysis was performed using the computed-based software Prism (version 6.00; GraphPad Software, La Jolla, California, USA). Continuous variables

were analyzed with Mann-Whitney and categorical one by using the Fisher exact test through a contingency table. Statistically significant differences were defined as those with $P < .05$.

RESULTS

During the study period, more than 750 patients underwent surgery for endometriosis and 121 patients were found to have involvement of the anterior compartment, 9 (7.4%) were lost to followup. Amongst the 112 patients who were followed up, we included 55 women in the study (49.1%) who wished to conceive at the time of surgery. Patients’ characteristics and surgical details are listed in **Table 1**.

Table 1.
Clinical and Surgical Characteristics of Study Population

Characteristic	Study Population (n = 55)
Age (years)	31 ± 3.4
Body mass index (kg/m ²)	26.1 ± 2.7
Duration of infertility (months)	18 ± 5.3
Preoperative ART	27 (49.1)
Previous medical treatment	7 (12.7)
Duration of surgery (minutes)	134 ± 52
Duration of hospitalization (days)	4 ± 2
Anterior compartment involvement	55 (100)
Bladder cystectomy	37 (67.3)
Bladder shaving	18 (32.7)
Ureterolysis	32 (58.2)
Monolateral	27 (84.4)
Bilateral	5 (15.6)
Anterior nodule size	2.9 ± 1.4
Posterior compartment involvement	30 (54.5)
Uterosacral ligament	30 (100)
Monolateral	24 (80)
Bilateral	6 (20)
Bowel resection	3 (10)
Bowel discoid resection	1 (3.3)
Bowel shaving	8 (26.7)
Follow-up duration (months)	25.6 ± 7.2

Note: values are median (range) or number (percent).
ART, assisted reproductive technologies.

During the 2-year followup, 26 patients (47.2%) conceived; among them, 17 (65.4%) conceived spontaneously and 9 (34.6%) after ART. The rate of miscarriage was 55.5% (n = 5) after ART and 0% after spontaneous conception, 21 patients of the 26 (80.7%) resulted in a live birth. Furthermore, 2 patients reported 2 pregnancies: one live birth and one miscarriage and 2 live births each one. The mean interval between surgery and conception was 8.6 ± 5.4 months (**Figure 4**).

Patients were divided into two groups accordingly to the occurrence of the endometriosis in the anterior compartment alone (n = 25) or the association with posterior compartment (n = 30). The pregnancy rate in those with anterior compartment involvement was 44% (n = 11) and 50% (n = 15) in the group with both anterior and posterior compartment involvement. There was no significant difference between the two groups ($P = .78$).

The overall rate of intraoperative complications was 7.3% (n = 4) occurring only in patients with posterior compartment involvement: 2 ureteral adventitia injury requiring double-J stent for 6 weeks, and 2 bowel perforations smaller than 1 cm occurred during the dissection, both managed with a primary repair not requiring a stoma. Despite the higher rate of intra-operative complications in the group of patients with surgical excision of disease in both compartments (7.3% vs 0%) the difference was not statistically significant.

Concerning bladder symptoms related to anterior compartment endometriosis 34.5% (n = 19) of patients reported preoperative dysuria, associated with haematuria in four cases.

Postoperative followup demonstrated complete resolution of symptoms in 84.2% (16/19) of the cases at the

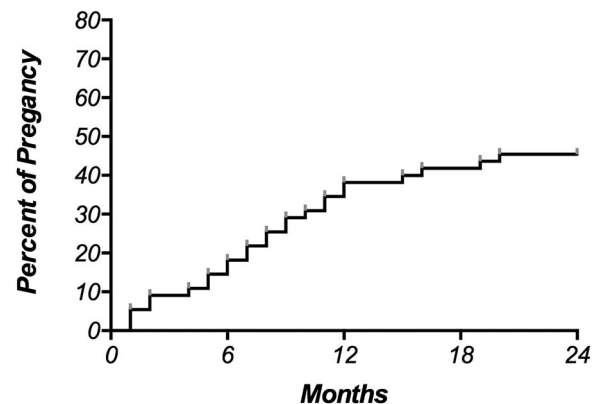


Figure 4. Kaplan-Meier estimates the time elapsed from surgery to conception.

short-term followup. Only three patients did not experience any improvement in urinary symptoms with complaints persistence at study time. None of them underwent further surgeries despite a bladder nodule was detected by MRI in one patient, as reported above.

The postoperative complication rate was 10.9% (n = 6): 2 haematomas and one urinoma requiring second look laparoscopy, and 3 vesico-vaginal fistulas.

The fistulas were successfully treated with double-J stent for 6 weeks and bladder catheter for an average of 30 days and 6 days' antibiotic therapy, a dye test with 250 mL of methylene blue was performed before the catheter was removed. On long-term followup, these patients had no sequel in term of urinary symptoms or pain.

The overall symptoms recurrence rate was 16.3% (n = 9) but only 1.8% (n = 1) had recurrence of the anterior compartment, which was detected at MRI causing symptoms of dysuria but not requiring further surgical intervention. In only 5 (9%) patients a lesion was detected either by MRI or ultrasound and the reoperation rate was 5.4% (n = 3): one had a lesion of the right round ligament causing inguinal pain which resolved following laparoscopic excision, and two patients experienced posterior compartment disease recurrence that required bowel resection.

DISCUSSION

To the best of our knowledge this is the first study evaluating reproductive outcomes following surgical treatment for DIE involving the anterior compartment in otherwise-unexplained infertile women.

This study demonstrates that deep endometriosis involving the anterior compartment negatively affects fertility. Furthermore, surgical excision of endometriotic lesions restored fertility in approximately half of the study population (11/26).

Despite the ongoing debate regarding the optimal treatment of deep endometriosis in infertile patients, it is recognized that this pathology impairs women's fertility, although the pathogenic mechanisms are still unclear.¹⁷ In cases of posterior compartment endometriosis the proposed mechanisms of disease progression are numerous, notably anatomy distortion resulting in pelvic adhesions with impaired tubal/oocyte interaction and altered peritoneal environment resulting in higher concentrations of inflammatory cytokines leading to reduces oocyte quality.¹⁸

However, unlike the posterior compartment involvement, which has been investigated in various studies with great interest among the authors, there is a distinct lack of data concerning anterior compartment endometriosis with no general consensus, leaving the management open to interpretation by physicians.

In this study, we found a pregnancy rate of 47.2% with a live-birth rate of 80.7% during the 2-year follow-up period in a selected group of patients with otherwise-unexplained primary infertility. When comparing pregnancy rate in patients affected by DIE involving both anterior and posterior compartment with those with anterior compartment disease alone we found no statistical difference, demonstrating that anterior compartment endometriosis plays a role in patients with infertility.

This division allowed us to consider a cohort of patients with urinary tract endometriosis alone, without any other forms of DIE, thus enabling us to evaluate the effectiveness of surgery on reproductive outcomes without the existence of other confounders. Therefore we are able to attribute the fertility improvement entirely to anterior endometriosis surgery, unlike other studies.^{11,19–21}

Fertility impairment can be mainly attributed to changes in the intraperitoneal environment, which, together with inflammation, could influence the easy reachability of the ovaries due to the constant peritoneal flow. Similarly, anatomical distortion may play a significant role in anterior endometriosis by fixing and accentuating the uterine anteversion, which could lead to a narrowing of the cervical canal causing not only difficulty in passing the sperm, but also retention of menstrual blood and secretions inside the uterus that compromise embryo implantation and sperm/oocyte interaction.

Although the difference in pregnancy rate was not significant in our series, patients with both anterior and posterior compartment involvement had a higher pregnancy rate after surgical treatment, probably attributed to the disease process causing greater inflammation in addition to a more severe anatomical disruption. These findings are in line with previous studies where multiple lesions at numerous locations has been demonstrated to have a higher negative impact on fertility.²²

In this series the pregnancy rate was slightly lower than in other published articles on bladder endometriosis where it ranges from 56% to 85%.^{11,15,20,23,24} However, we should take into account that the primary goal of these studies was not fertility and in some cases the assessment of preoperative fertility was lacking. Fur-

thermore, the population of these studies was not composed of infertile patients, as it is in our study; this is the main strength of our paper and makes the results incomparable.

The absence of a control group is a weak point of this study but in our opinion the surgical approach was appropriate since it would have been unethical to propose expectant management. Secondly, endometriosis is a heterogeneous condition that makes two groups difficult to compare; however, the patients can be compared with themselves before the surgery reducing the bias in patients selection.

Another factor that could impair fertility in patients with DIE is the coexistence of adenomyosis,²⁵ which may lead to difficult embryo transport and implantation due to an abnormal peristaltic pattern.¹⁷ Given the retrospective nature of the study, we were unable to rule this out.

One of the main recognized arguments regarding DIE affecting fertility is that a deep lesion may not be able to influence the peritoneal cavity because it remains buried beneath the adhesions and the peritoneum suggesting that the treatment of superficial implants alone may be sufficient to treat infertility.²⁶ Although, the disease itself is theoretically classified into superficial and deep endometriosis, often the two coexist and it is impossible to discriminate the two components especially in advanced staged.

Furthermore, it would be unethical to propose to a patient who opted for surgery to treat only superficial disease, leaving a substantial part of it in place, which could significantly contribute to the patient's symptoms and influence her quality of life. Moreover, there is increasing evidence suggesting that surgical excision of deep lesions is not only effective in relieving painful symptoms but also in restoring fertility.²⁷

Regarding painful symptoms related to deep infiltrating anterior endometriosis, we observed a complete resolution of symptoms in 84.2% of patients. Only 3 patients at the end of the study experienced only a pain improvement without complete resolution of symptoms. This is in line with the data reported by Seracchioli et al,⁹ where no recurrence of disease occurred and only 3.5% of patients reported persistence of dysuria. Although some patients experienced relapse of symptoms, there was no need for further surgery intervention during the 2-year followup, unlike that described in previous studies.^{11,23,24}

Surgical treatment of DIE requires great skills and experi-

ence because it is not free of complications and we should always find a balance between radicality and risk of complications.²⁸ The more radical we are, the higher the risk of complication,^{29,30} but equally the complete excision of lesions at the first surgery plays a pivotal role in improving reproductive outcomes, the quality of life, the painful symptoms, and reduces the chance of disease recurrence.^{9,10,31,32}

In our study, the overall rate of intraoperative complications was 7.3%. In all instances, this occurred in patients with DIE affecting the posterior compartment. There were, however, no complications in patients with anterior compartment disease alone in line with other series.²⁴ We could suggest that the presence of multiple disease locations and the involvement of the posterior compartment of the pelvis increase the surgical difficulty and as a consequence the possibility of complications.³³

We observed a postoperative complication rate of 10.9%, lower than that described by Rozsnyai et al,²⁰ where the postoperative complication rates after ureteral surgery and bladder surgery were 25% and 13% respectively. Concerning major complications, requiring further surgical intervention, 5.4% of patients underwent a second-look laparoscopy, in keeping with the literature where it ranges from 2.7% to 9%.^{10,24}

Almost 50% of patients performed ART preoperatively with negative results, we are aware that it represents a bias since it can not be excluded that if the other patients had undergone ART they would have obtained a pregnancy without surgery. However the percentage of postoperative ART is lower than the preoperative one and this does not invalidate our results.

Despite the small number of patients in this retrospective series, it remains one of the largest with a specific selection criteria of patients (unexplained infertile patients, negative history for previous surgery, etc.) in an attempt to limit confounding factors present in other studies.^{9,11,19} We believe that these aspects could reduce at least some of the confounders and bias quoted by Somigliana et al²⁶ in the evaluation of postsurgical pregnancy rates.

To conclude, endometriosis adversely affects fertility and its surgical treatment improves reproductive outcomes. Furthermore, there are encouraging data linking the eradication of anterior compartment DIE with restored fertility.

Timing of surgery should be tailored according to the patient wishes based on surgical history, painful symptoms, and desire to conceive.

Patients should be appropriately counseled and informed that the treatment of anterior compartment endometriosis is effective in relieving pain and it is associated with very low recurrence rates. In addition, they should be made aware that the rate of complications increases exponentially in case of posterior compartment disease involvement where more radical excision of the disease may be adopted.

References:

1. Nezhat C, Nezhat F, Nezhat CH, Nasserbakht F, Rosati M, Seidman DS. Urinary tract endometriosis treated by laparoscopy. *Fertil Steril*. 1996;66(6):920–924.
2. Chapron C, Fauconnier A, Vieira M, et al. Anatomical distribution of deeply infiltrating endometriosis: Surgical implications and proposition for a classification. *Hum Reprod*. 2003;18(1):157–161.
3. Antonelli A, Simeone C, Zani D, et al. Clinical aspects and surgical treatment of urinary tract endometriosis: Our experience with 31 cases. *Eur Urol*. 2006;49(6):1093–7; discussion 1097–1098.
4. Villa G, Mabrouk M, Guerrini M, et al. Relationship between site and size of bladder endometriotic nodules and severity of dysuria. *J Minim Invasive Gynecol*. 2007;14(5):628–632.
5. Kołodziej A, Krajewski W, Dołowy Ł, Hirnle L. Urinary tract endometriosis. *Urol J*. 2015;12(4):2213–2217.
6. Panel P, Huchon C, Estrade-Huchon S, Le Tohic A, Fritel X, Fauconnier A. Bladder symptoms and urodynamic observations of patients with endometriosis confirmed by laparoscopy. *Int Urogynecol J*. 2016;27(3):445–451.
7. Zupi E, Centini G, Lazzeri L. Urinary tract endometriosis: A challenging disease. *Fertil Steril*. 2015;103(1):41–43.
8. Leone Roberti Maggiore U, Ferrero S, Candiani M, Somigliana E, Viganò P, Vercellini P. Bladder endometriosis: A systematic review of pathogenesis, diagnosis, treatment, impact on fertility, and risk of malignant transformation. *Eur Urol*. 2017;71(5):790–807.
9. Seracchioli R, Mabrouk M, Montanari G, Manuzzi L, Concetti S, Venturoli S. Conservative laparoscopic management of urinary tract endometriosis (UTE): Surgical outcome and long-term follow-up. *Fertil Steril*. 2010;94(3):856–861.
10. Chapron C, Bourret A, Chopin N, et al. Surgery for bladder endometriosis: Long-term results and concomitant management of associated posterior deep lesions. *Hum Reprod*. 2010;25(4):884–889.
11. Soriano D. Reproductive outcome is favorable after laparoscopic resection of bladder endometriosis. *J Minim Invasive Gynecol*. 2016;23(5):781–786.
12. Ajao MO, Einarsson JI. Management of endometriosis involving the urinary tract. *Semin Reprod Med*. 2017;35(1):81–87.
13. Fraser IS, Critchley HO, Broder M, Munro MG. The FIGO recommendations on terminologies and definitions for normal and abnormal uterine bleeding. *Semin Reprod Med*. 2011;29(5):383–390.
14. Gustilo-Ashby AM, Paraiso MF. Treatment of urinary tract endometriosis. *J Minim Invasive Gynecol*. 2006;13(6):559–565.
15. Kovoov E, Nassif J, Miranda-Mendoza I, Wattiez A. Endometriosis of bladder: Outcomes after laparoscopic surgery. *J Minim Invasive Gynecol*. 2010;17(5):600–604.
16. Afors K, Murtada R, Centini G, et al. Employing laparoscopic surgery for endometriosis. *Women's Heal*. 2014;10(4):431–443.
17. Somigliana E, Viganò P, Berlanda N, Vercellini P, Benaglia L, Busnelli A. Management of endometriosis in the infertile patient. *Semin Reprod Med*. 2017;1(35):31–37.
18. Harris-Glocker M, McLaren JF. Role of female pelvic anatomy in infertility. *Clin Anat*. 2013;26(1):89–96.
19. Fleisch MC, Xafis D, De Bruyne F, Hucke J, Bender HG, Dall P. Radical resection of invasive endometriosis with bowel or bladder involvement—Long-term results. *Eur J Obstet Gynecol Reprod Biol*. 2005;123(2):224–229.
20. Rozsnyai F, Roman H, Resch B, et al. Outcomes of surgical management of deep infiltrating endometriosis of the ureter and urinary bladder. *J Soc Laparoendosc Surg*. 2011;15(4):439–447.
21. Leone Roberti Maggiore U, Ferrero S, Candiani M, Somigliana E, Viganò P, Vercellini P. Bladder endometriosis: A systematic review of pathogenesis, diagnosis, treatment, impact on fertility, and risk of malignant transformation. *Eur Urol*. 2017;71(5):790–807.
22. Centini G, Lazzeri L, Dores D, et al. Chronic pelvic pain and quality of life in women with and without endometriosis. *J Endometr*. 2013;5(1):27–33.
23. Schonman R, Dotan Z, Weintraub AY, et al. Deep endometriosis inflicting the bladder: Long-term outcomes of surgical management. *Arch Gynecol Obstet*. 2013;288(6):1323–1328.
24. Saavalainen L, Heikinheimo O, Tiitinen A, Härkki P. Deep infiltrating endometriosis affecting the urinary tract-surgical treatment and fertility outcomes in 2004–2013. *Gynecol Surg*. 2016;13(4):435–444.
25. Di Donato N, Montanari G, Benfenati A, et al. Prevalence of adenomyosis in women undergoing surgery for endometriosis. *Eur J Obstet Gynecol Reprod Biol*. 2014;181:289–293.
26. Somigliana E, Garcia-Velasco JA. Treatment of infertility as-

sociated with deep endometriosis: Definition of therapeutic balances. *Fertil Steril*. 2015;104(4):764–770.

27. Dunselman GA, Vermeulen N, Becker C, et al. ESHRE guideline: Management of women with endometriosis. *Hum Reprod*. 2014;29(3):400–412.

28. Zupi E, Lazzeri L, Centini G. Deep endometriosis: Less is better. *J Endometr*. 2015;7(1):1–2.

29. Minelli L, Ceccaroni M, Ruffo G, et al. Laparoscopic conservative surgery for stage IV symptomatic endometriosis: Short-term surgical complications. *Fertil Steril*. 2010;94(4):1218–1222.

30. Alabiso G, Alio L, Arena S, et al. How to Manage Bowel

Endometriosis: The ETIC Approach. *J Minim Invasive Gynecol*. 2015;22(4):517–529.

31. Centini G, Afors K, Murtada R, et al. Impact of laparoscopic surgical management of deep endometriosis on pregnancy rate. *J Minim Invasive Gynecol*. 2016;23(1):113–119.

32. de Ziegler D, Borghese B, Chapron C. Endometriosis and infertility: Pathophysiology and management. *Lancet (London, England)*. 2010;376(9742):730–738.

33. Alves J, Puga M, Fernandes R, et al. Laparoscopic management of ureteral endometriosis and hydronephrosis associated with endometriosis. *J Minim Invasive Gynecol*. 2017;24(3):466–472.